Chapter 5
Academic Knowledge: Medical Terminology and Body Organization

PROFESSIONAL VOCABULARY

You will need to learn the essential terms listed below before you begin your reading. These terms will help you understand the main concepts of the chapter. These terms, which will be highlighted in yellow within the text, will become part of your professional vocabulary.

In addition to these essential terms, you will see bold terms throughout the chapter. The meanings of these terms are explained where the terms first appear. The bold terms, like the essential terms listed here, will become part of your professional vocabulary and deepen your understanding of the topics presented.

abdominal region one of nine equal areas of the abdomen that are named and used as reference points when discussing the body

anatomy the physical structures or parts of the body

body cavity a hollow space within the body that is lined by a membrane and contains bodily organs

body plane a flat or level surface seen by cutting away part of the body through surgery or medical imaging to serve as a point of reference when discussing anatomy

body region an area of the body with a specific name, which is used as a reference point when discussing anatomy

body system a group of organs working together to perform a vital function in the body

cell a small group of organelles that fulfill a specific purpose and are held together by a membrane

medical terminology special vocabulary that is used in healthcare and is often formed from Latin and Greek word parts

mnemonic device a learning tool that helps students memorize information

organ a distinct body structure made of different tissues working together for the same purpose

organelle a part of a cell that has a specific task

physiology the functions or inner workings of the body

standard anatomical position (SAP) the agreed-upon reference for body position when studying anatomy; standing erect on two legs, facing frontward, with the arms at the sides and palms facing forward

tissue a group of cells of the same type working together for the same purpose

CONNECT WITH YOUR READING

Before you read this chapter, organize the terms in the *Maximize Your Professional Vocabulary* list at the end of the chapter into logical categories based on your current knowledge. Use arrows or circles to show connections between related terms as needed. Share your newly organized list with a partner and discuss the differences in how you organized the terms.

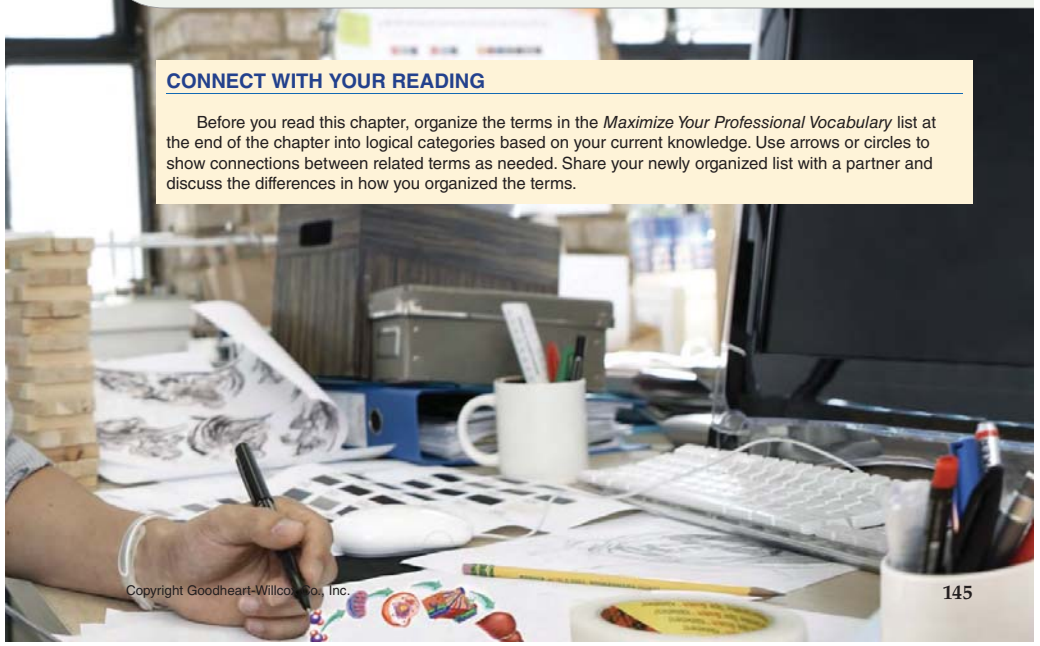

MAP YOUR READING

Make a tablet organizer with four sheets of paper using the template shown at the left. Stack the sheets, keeping the sides even, but move each sheet of paper up so that its bottom edge is ½ inch to 1 inch above the bottom edge of the sheet below it. Holding the center of the stack, fold all the sheets down so the top edge of the top sheet is ½ inch to 1 inch above the bottom edge of the top sheet. Crease all the layers and staple at the folded edge. Write *Understanding Body Organization* on the outside flap and list what you know about the organization levels in the body. Label the edges of the flaps below the top one with the headings *The Cell*, *Body Tissues*, *Organs*, *Body Systems*, *Body Directions*, *Body Regions and Quadrants*, and *Body Cavities and Planes*. As you read, add visual cues, definitions of new terms, and notes on important concepts to each page of the booklet.

Knowledge of the body's anatomy and physiology is important for all healthcare workers. Information about how the body is organized is the foundation on which all other academic knowledge for healthcare workers is based. Learning the anatomy of the body means that you will be learning many new terms. This may seem overwhelming and you may need some new strategies for studying this new information.

In this chapter, you will be introduced to the language of medicine and techniques to help you learn new terminology and anatomy more quickly. Through these concepts, you will learn about the organization of the human body, including the directions and regions that are used to describe anatomy. You will also learn about the anatomy and physiology of the cell. After reading this chapter, you will be prepared to look at each body system in more depth in future chapters.

Study Skills for Health Science Students: Memory Techniques

It is nearly impossible to memorize all the medical terms you will hear in class or in the workplace, but learning some of the more common word parts will make it easier to understand the spoken and written terms used in patient care. It will also help you figure out the general meanings of body structures, diseases, and procedures. You will need to develop some ways to remember the large amount of information used in healthcare.

Memory Techniques for Learning Terms

People use a variety of methods to help them study and remember new terms. One common technique is to make and use flash cards. The time spent creating and reviewing the cards is what makes this technique work, so develop games or a schedule to use them often.

Some people play with the way a word looks to help remember its meaning. For example, *parallel* means *equal* and the *ll* in the middle of the word looks like a sideways equal sign. When studying a term, try creatively drawing or reshaping the letters.

Another technique is to look for familiar words that share the same word part, such as *ortho*dontists who straighten teeth and *ortho*pedists who straighten bones. This strategy may be used with everyday English words, too.

Some students like to investigate the origins of a new word. For example, *hypochondriac* [*hypo* = below, *chondr* = cartilage, *ac* = pertaining to] literally means *pertaining to the area below the cartilage*. However, in medical usage, it means *below the ribs* because some of the ribs are attached by cartilage. The term *hypochondriac* may also be used to mean a person who always thinks he or she is ill. Interestingly, many of us hold the area under our ribs when we complain that we don't feel well.

This book breaks medical terms down into their Latin and Greek origins to help you understand their meanings. All of the techniques described here can help you build a better vocabulary of new terms.

Mnemonic Devices

Mnemonic (nih-MAH-nihk) **devices** can be used to remember information. Sounds, colors, smells, tastes, touch, and emotions are all stored in different areas of the brain. By vividly connecting information with many senses, it is easier to recall the information later. The following are suggestions for basic techniques:

mnemonic device
a learning tool that helps students memorize information

- Make up acronyms to remember the parts of a concept or procedure. For example, the acronym *SOMBER* can remind you of the symptoms of depression—Sadness, Overwhelmed, Memory problems, Behavioral changes, Eating changes, and Restlessness.
- Use the spelling sequence of a word to remember the order of items in a list. For instance, *SOAP* tells you the steps in the system for recording narrative progress notes are Survey/Subjective, Observation/Objective, Assessment, and Planning.
- Use rhythm and rhyming to recall information. For example, "*i* before *e* except after *c*" reminds you of a basic spelling rule. You can also create lyrics from information and set them to a familiar tune or make up one of your own.
- Play the sound of the word you are learning off the sound of a word you already know. For instance, the word part *later*, which means *side*, sounds like *ladder*. To remember this term, you can imagine climbing up the side of a ladder.
- Use vivid or unusual images to recall new terms. Try imagining a deck of playing cards for the term *cardi*. This means *heart*, so you might see yourself holding a handful of pulsing, bloody hearts during your card game. The more vivid and unusual the image, the better.
- Exaggerate the size of important parts of an image. For example, a motor homunculus (hoh-MUHN-kyuh-luhs) [*homin* = human, *ule* = small, *us* = structure] is an exaggerated drawing used to help you recall how much area in the brain is required for muscle control of the different parts of the body (Figure 5.1). It has a very

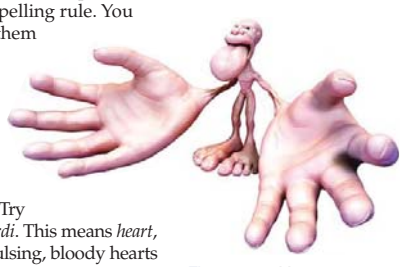

Figure 5.1 You can exaggerate important aspects of a term or image to better remember it. Which term in this chapter could you memorize by creating an exaggerated visual representation?

large tongue, lips, eyes, and hands to show that these parts use a larger area of the brain for motor control than the legs or nose. You can create an exaggerated image like the homunculus for whichever term you're trying to learn.

- Create a short scene with dramatic voices and actions to go with the information you are trying to remember, then practice acting it out. You will remember that the "brachial region" is on your arm if you hold your arm and say in a childish voice, "I breaky my arm!"
- Use humor, especially if it is shocking. This can make things very hard to forget. For example, you might think of the interesting contrast between *cleave*, which means *to cut or split apart*, and *cleavage*, which is created by pressing the breasts together.

The more strongly you can picture what you are trying to learn and associate it with something you already know, the more easily you will recall it later. Make your learning more memorable by using all of your senses as you study.

Complete the *Map Your Reading* graphic organizer for the section you just read.

RECALL YOUR READING

1. _____ devices can help students remember and organize new information.
2. Vividly connecting information with many _____ makes it easier to recall information later.
3. _____ use the first letters of each word to make a new word.
4. Use the _____ sequence of a word to remember the order of items in a list.

Medical Terminology

medical terminology special vocabulary that is used in healthcare and is often formed from Latin and Greek word parts

Healthcare workers use a special language called **medical terminology** to communicate clearly about their patients. Understanding and using medical terminology is like speaking a foreign language. It takes effort and practice to speak another language, such as Spanish or French. You will find the same is true as you study medical terminology. Most medical terms come from Greek and Latin root words. Learning these origins may help you understand and remember terms.

All healthcare workers must be able to read, write, and understand medical terminology so they can communicate clearly with other professionals about their patients. Some healthcare workers, such as medical transcriptionists, will spend most of their day reading and writing medical terms. The ability to understand written and spoken medical terminology is essential to prevent errors at all stages of care and treatment.

Abbreviations

Abbreviations provide a shortened way to write or say medical words and phrases. You are already familiar with many abbreviations used in

everyday language, such as *a.m.* and *p.m.* for morning and afternoon. Abbreviations are an important part of medical terminology. They can save time, space, and effort.

An abbreviation can be a shortened form of a word. For instance, *chemo* is a shortened way of saying *chemotherapy*. Some abbreviations are known as **acronyms**, meaning that each letter in the abbreviation stands for a word. For example, MRI is an acronym for *magnetic resonance imaging*. Sometimes each letter of an abbreviation represents a Greek or Latin word part, as in ECG, which is an abbreviation for *electrocardiography*. These abbreviations may not make sense until you understand their Latin and Greek origins.

Different medical facilities in different parts of the country may write abbreviations in different ways. Some use a period to separate lowercase letters, as in *b.i.d.* for *twice in a day*. Some use all capital letters, as in *BID*. Different facilities may or may not have lines over certain abbreviations. The abbreviation for *after* may be written as either $\overline{p}$ or *p*, depending on the facility in which you work.

Both writing messily and misreading letters and numbers that look alike can cause preventable medical errors (Figure 5.2 on the next page). Healthcare workers should be aware of and use only the abbreviations on the approved list for their facility. Never make up your own abbreviations. Use your best judgment about when abbreviations are helpful and when they should be avoided to prevent additional confusion. Always write neatly. Medical charts are a legal record and must be understandable for everyone who uses them.

Understanding Word Parts

Every language has rules that determine how it is properly written and spoken. The rules are different for each language. Medical terminology, like any other language, also follows specific rules for how words are formed, spelled, and pronounced.

A medical term is usually a combination of several word parts, like a train with many types of boxcars connected together (Figure 5.3 on the next page). Breaking down medical terms into their various parts will allow you to define many more terms than you could possibly memorize by studying them as whole words. Examples of all word parts are provided in Figure 5.4 on page 151.

A **root word** is the foundation of a medical term. It carries the term's main meaning, just as a train's boxcars hold the cargo to be delivered. It is usually a noun, such as a body part. For example, the root word *cardi* means *heart*, and the root word *pulmon* means *lung*.

Several root words may be combined in one word, like a compound word, but they need a **combining vowel** to connect them when the next root does not begin with a vowel. Think of combining vowels like couplers that hold a train's boxcars together. The most common combining vowel is *o*, but other vowels may sometimes be used. A combining vowel makes the complete term easier to pronounce. The word *cardiopulmonary* sounds smoother than *cardipulmonary* because of the letter o placed between the root words.

Figure 5.2 Error-Prone Abbreviations and Symbols

Error-Prone Abbreviation or Symbol	Intended Meaning	Misinterpretation	Solution
l	lowercase *l*	numeral 1	Write in block letters and provide space between a word ending in *l* and a number following it.
1	numeral 1	lowercase *l*	When a quantity follows another word, place the number on the next line or provide enough space between words and numbers.
0	numeral 0	letter *o*	Use the word *zero*.
Z	letter *Z*	numeral 2	Use European-style letter (Ƶ).
7	numeral 7	numeral 1	Use European-style seven (ϒ).
/	slash to separate items, meaning *per*	numeral 1	Use the word *per*.
cc	cubic centimeters (units)	numerals 00 *or* letters *oo*	Use *mL*.
HS or hs	half-strength *or* hour of sleep (bedtime)	hour of sleep (bedtime) *or* half-strength	Use the words *half-strength* or *bedtime*.
QOD	every other day	Q.D. (every day)	Use the words *every other day*.
no leading zero before a decimal point	.5 mg	5 mg (if the decimal is missed)	Write a zero to the left of the decimal when a number is less than a whole unit.
measurement abbreviations with a period following the abbreviation	mg. or mL.	period is unnecessary and could be interpreted as a number if writing is messy	Use *mg*, *mL*, or *etc*, without the period.

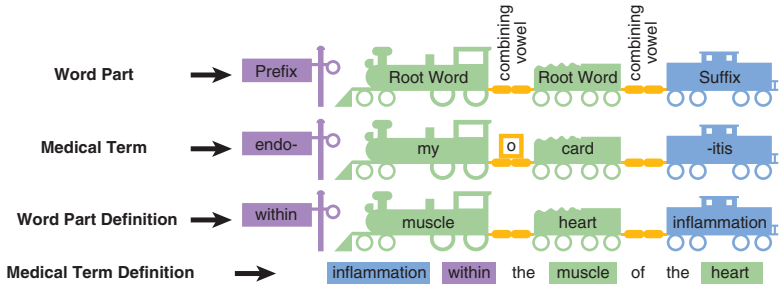

Figure 5.3 "Word trains" like these provide visuals to help you understand different parts of words.

Figure 5.4 Word Parts

Word Part	Purpose	Location	Use of Connecting Vowel	Example	Explanation
prefix	changes, adds to, or limits the meaning of the root; may tell you size, shape, color, position, or amount; is frequently a preposition or an adverb (not all words have a prefix)	beginning of the word	No connecting vowel is needed between the prefix and root word.	bi-	bi- = two bifocals = eyeglasses with two portions in each lens to adjust for both near and far vision
root word	main meaning of the word; usually a noun, such as a body part	middle of the word (or the beginning of the word if there isn't a prefix)	Drop the connecting vowel if the next word part begins with a vowel.	dent- or dento-	dent- = tooth dentist = a doctor who examines teeth and treats teeth-related health issues
suffix	changes the meaning of the root; makes the term a noun, an adjective, or a verb and tells what is being done to the root	end of the word	Use a connecting vowel if the suffix begins with a consonant.	-ology	-ology = the study of physiology = the study of nature
connecting vowel	makes it easier to pronounce the term	between word parts	When there is more than one root word, use a connecting vowel between the root words. When the suffix begins with a consonant, use a connecting vowel between the root and suffix.	-o-	musculoskeletal = muscul-**o**-skelet-al

A **prefix** [*pre* = before] appears at the beginning of a word, like a signal light in front of a train. The light tells the engineer whether to change the train's route or speed, just as the prefix can change, add to, or limit the meaning of the root word. The prefix may tell you the size, shape, color, position, or amount of the root. A combining vowel is not usually needed between a prefix and a root word. Not all words have a prefix.

A **suffix** appears at the end of a word, like the caboose of a train. It tells you what is being done to the root word, just as a brakeman used to ride in the train caboose to watch how the train and brakes were operating. The suffix can change the root into an adjective, a noun, or a verb. It can also add to the meaning of the root. It may identify size or describe a condition or procedure. If a suffix begins with a vowel (*a*, *e*, *i*, *o*, *u*, and sometimes *y*), it attaches directly to the root. If a suffix begins with a consonant (*b*, *c*, *d*, *f*, and so on), a connecting vowel is needed between the root and the suffix. All medical terms have at least one root and a suffix.

Creating a **plural** word in medical terminology does not follow the same rules as Standard English. In Standard English, the suffix *-s* or *-es* is added to show there is more than one. This is often not appropriate in medical terminology. Different plural endings are used with different Latin and Greek suffixes (Figure 5.5).

Defining medical terms is like solving a puzzle. To discover the meaning of a term, you will need to break it down into its individual parts and define each part. Define the suffix first, and then define the remaining word parts from left to right. Combine the definitions of the word parts to discover the meaning of the whole term. For example, *cardiopulmonary* can be broken into *cardi* (which means *heart*), *o* (the combining vowel), *pulmon* (which means *lung*), and *-ary* (which means *pertaining to*). Together they mean *pertaining to the heart and lung*.

Practice analyzing medical words that you see and hear. A medical dictionary will be an important tool when a term comes from a proper name, cannot be broken down, or has an unclear meaning. However, you will be able to understand the general meaning of most medical terms quickly by interpreting the word parts.

Pronunciation and Spelling

Healthcare workers also need to become comfortable reading and saying medical terms. These terms may seem hard to pronounce, especially if you haven't already heard them spoken. Many medical words have similar and sometimes confusing sounds. They may also look long

Figure 5.5 Plural Forms of Common Latin and Greek Suffixes

Ending	Singular Forms	Drop	Add	Plural Forms
-y	deformity, family	-y	-ies	deformities, families
-is	diagnosis, fibrosis	-is	-es	diagnoses, fibroses
-us	alveolus, stimulus	-us	-i	alveoli, stimuli
-um	ileum, bacterium	-um	-a	ilea, bacteria
-a	vertebra, ruga	-a	-ae	vertebrae, rugae
-ma	sarcoma, melanoma	-ma	-mata	sarcomata, melanomata
-ax	thorax, anthrax	-ax	-aces	thoraces, anthraces
-ex	cortex, index	-ex	-ices	cortices, indices
-ix	appendix, matrix	-ix	-ices	appendices, matrices
-on	spermatozoon, protozoon	-on	-a	spermatozoa, protozoa
-en	foramen, lumen	-en	-ina	foramina, lumina
-nx	larynx, pharynx	-x	-ges	larynges, pharynges
-yx	calyx	-yx	-yces	calyces

and difficult. These tips will help with pronunciation. First, break each term into its word parts. Then pronounce each word part separately. Figure 5.6 provides some basic pronunciation rules. The part of the word that appears in capital letters should be emphasized when you speak.

Although these rules will help you pronounce new terms, medical words should not be spelled by sounding them out. Some terms sound alike but are spelled differently. One letter can change the entire meaning of a body part or drug name. If you misspell a medical term, it can create confusion and may result in an incorrect diagnosis or procedure. You cannot rely on a computer to find your errors because spell-checkers may not recognize medical terminology. When you are unsure of a term's spelling or meaning, you should look up the term in a medical dictionary.

Figure 5.6 Pronunciation Rules

Rule	Examples
• *c* and *g* have a soft sound (like *s* and *j*) when they appear before the letters *e*, *i*, and *y*	cycle (SI-kuhl) gender (JEHN-der) giant (JI-ant)
• *c* and *g* have a hard sound (like *k* and *guh*) when they appear before other letters	cranium (KRAY-nee-um) cut (KUHT) gonad (GOH-nad)
• *ch* sounds like *k* when it appears before consonants	chlorine (KLOHR-een) chronic (KRAHN-ik)
• *p* is silent at the beginning of a word when followed by the letters *s* and *n*	psychic (SI-kik) pneumonia (noo-MOH-nyuh)
• *i* sounds like *eye* when added to the end of a word to form a plural	stimuli (STIM-yoo-li) alveoli (al-VEE-oh-li)
• *ae* and *oe* sound like *ee*	coxae (kahk-SEE) amoeba (uh-MEE-buh)
• *es* is often pronounced as a separate syllable when found at the end of a word	nares (NAR-eez) stases (STAYS-eez)

RECALL YOUR READING

1. In all medical careers, it is important to understand, speak, spell, and use _____ correctly.
2. All medical terms have one or more _____ and a _____, but they may not have a _____.
3. It is important that you use only the _____ accepted by your facility.
4. _____ medical terms may not be formed by adding *-s* or *-es* to the end, as in common English words.
5. _____ rules can be used to sound out medical terms, but there may be more than one spelling for a particular sound.

Complete the *Map Your Reading* graphic organizer for the section you just read.

Body Organization and Related Medical Terms

anatomy
the physical structures or parts of the body

physiology
the functions or inner workings of the body

When healthcare workers discuss body systems, the parts of the body are its **anatomy** and how the body works is its **physiology** (fih-zee-AH-luh-jee) [*physi* = nature, *ology* = the study of]. Anatomy and physiology work together. The shape and location of a body part tells you a lot about what it does.

The anatomists who drew and studied the parts of the body hundreds of years ago spoke Greek and Latin, which explains the origins of our medical terms. Today, pathophysiologists (path-oh-fihz-ee-AHL-uh-jihsts) study *pathologies*, or diseases and disorders that occur when the body isn't functioning properly. All healthcare workers must understand anatomy and physiology so they can recognize what is normal and where a problem may exist. A medical coder's knowledge of anatomy will help them identify a code for a procedure that doesn't match the body part mentioned in the record. Many discoveries and treatments are developed by studying the body and its functions.

Your body structures are put together in a very organized way. Each level of organization builds on the next to form a larger structure (Figure 5.7). At the smallest level are atoms, which bond together to form molecules (MAHL-uh-kyoolz). For example, hydrogen (H) and oxygen (O) atoms combine to form a molecule of water (H_2O). Groups of molecules form **organelles**, which are the structures within cells. Cells join together to form tissues. Different types of tissues work together as a body organ. A body system is a group of organs that perform a vital function in the body. All of these parts function together to form a living organism.

organelle
a part of a cell that has a specific task

Molecular biologists study life at the cellular level. The information they discover about how genes, DNA, bacteria, and viruses work in a cell help healthcare professionals diagnose, prevent, and treat diseases. Biotechnology uses information about how microorganisms work to stay on the cutting edge of these types of discoveries.

The Cell and Its Organelles

cell
a small group of organelles that fulfill a specific purpose and are held together by a membrane

A **cell** is considered the smallest living thing. It is so small that it usually can't be seen without a microscope. Even though it is small, a cell is capable of performing all the activities that define life. Biologists say something is living if it can take care of its own structures, interact with its environment, grow, and reproduce. Cellular biologists study how the chemical reactions of cells can be supported or manipulated. Therefore, chemistry is very important in healthcare careers that require an understanding of how the body works. Some of the cellular structures will be covered in more detail in chapter 21.

The word *cell* comes from the Latin word *cellula*, which means "small room." You can think of each cell in your body as a room in a factory, creating a product or doing a job for that factory. Cells may have specialized roles as nerve, bone, blood, epithelial, or muscle cells. Although each room in your factory has the same basic structure and furniture, different rooms need special equipment for their specific jobs. Different types of cells also have the same basic parts, or *organelles*, but

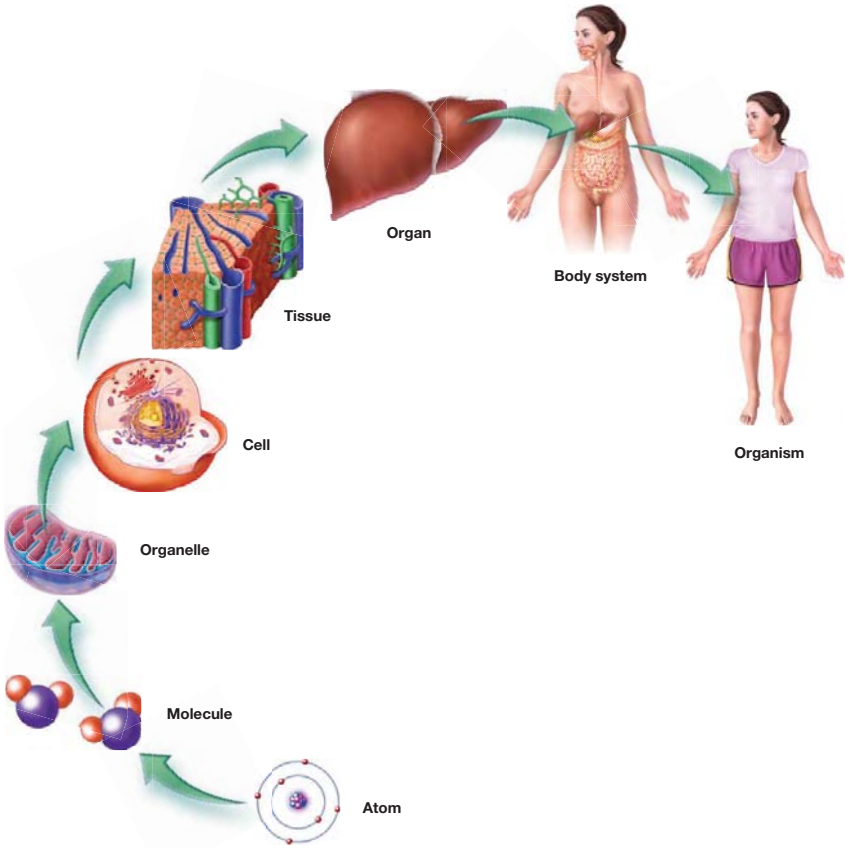

Figure 5.7 The organizational hierarchy of the body, from atom to organism, is shown here. What are some examples of organelles, organs, and body systems?

they contain different amounts and kinds of organelles depending on the cell's purpose. The anatomy or structure of a cell is closely related to its physiology, or function.

The cell's organelles can be seen as the furnishings and equipment in a factory (Figure 5.8). Every factory room needs walls for structure and protection from the environment outside, but also windows and doors to allow some things in and out. Similarly, the **cell membrane** is a semipermeable (sehm-ee-PER-mee-uh-buhl) [*semi* = half] outer covering with holes, or *pores*, that act as its doors and windows. Some

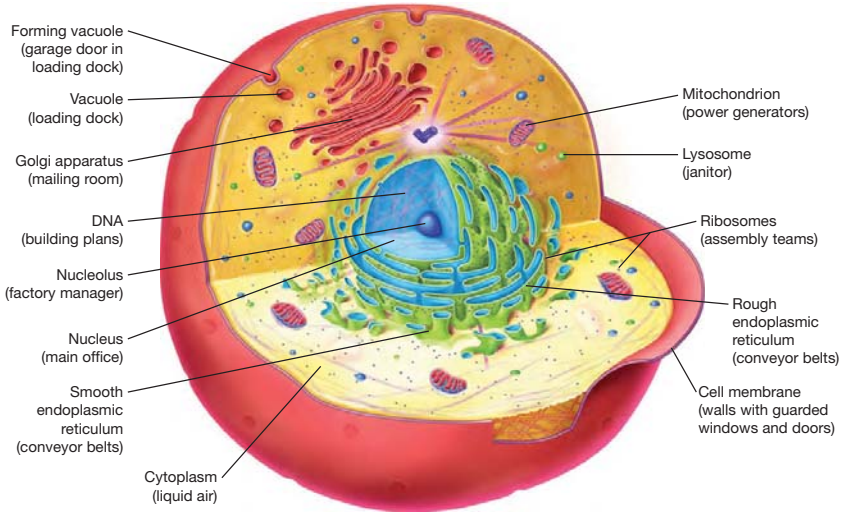

Figure 5.8 The parts of a cell can be compared to different parts of a factory. Choose one cell part and compare it to its corresponding factory component.

molecules can easily pass through the "security guards" at these pores; other molecules require cell energy to be carried actively through the membrane. **Vacuoles** (VAK-yu-wohlz) are like the doors of the loading dock. They allow larger enzymes and waste molecule packages to pass through the cell membrane. Fat cells have large vacuoles and not many other organelles. Cells use chemical messages to communicate about which materials need to be allowed through the membrane.

The cell membrane may have other structures that fulfill special needs. If a cell needs to be able to move, as with sperm, then it may have a flagellum (fluh-JEHL-uhm), or *tail*, as part of its cell membrane. This is like having a scooter to get around your factory. Some cells, like those of the intestines, need to absorb fluids or nutrients from the environment like a sponge. These cells have tiny hairs called cilia (SIHL-ee-ah) to increase the available surface area of their outer membrane. Just as air is contained within the walls of a factory, a semifluid **cytoplasm** (SI-toh-plaz-uhm) [*cyt* = cell, *plasm* = formation, structure] is contained within the walls of a cell. Chemical reactions take place in the cytoplasm as parts of the cell communicate and complete their work.

The **nucleus** is the factory's main office. It controls the cell's activity. The **nucleolus** (noo-KLEE-oh-luhs), located at the center of the nucleus, is the factory manager. It uses assembly teams called **ribosomes** (RI-buh-sohmz) to build proteins following the **DNA (deoxyribonucleic acid)** plans. The DNA are complete plans for items the cell builds. The nucleus interprets these directions and tells the cell what to build and when

to build it. It also makes copies and produces its own new cells when needed.

Factories often use a conveyer belt to sort and transport materials for production. **Endoplasmic reticulum** (ehn-doh-PLAZ-mihk rih-TIHK-yuh-luhm) [*endo* = within, *plasm* = structure, *ic* = pertaining to, *reticulo* = network, *um* = structure], or *ER*, in the cell is like a conveyor belt on the production floor, moving construction materials (ribosomes) in and out of the nucleus as they are assembled. Rough ER is covered with ribosomes from the nucleus for building proteins. Smooth ER builds and stores fats and carbohydrates and detoxifies harmful substances. The **Golgi apparatus** (GOHL-jee ap-uh-RAT-uhs) is made up of layers of membranes in the cytoplasm that function like a mailing room. This organelle inspects, sorts, and packages proteins for use within or removal from the cell.

Cells and factories require energy to operate. Power stations provide energy to factories. **Mitochondria** (mI-toh-KAHN-dree-a) are power stations for cells. They produce adenosine triphosphate (ATP) from carbohydrates, fats, and proteins. Breaking the bonds of ATP creates energy for the cell. Muscle cells have more mitochondria than other cells because their work requires a lot of energy. After cells have used the available energy, digestive enzymes in the **lysosomes** (LI-suh-sohmz) [*lysis* = destruction] destroy used, dead, and foreign materials that are left behind, much like a factory janitor cleans up after workers.

Different types of cells have different functions, and each organelle has a different task within the cell. A cell may have more or fewer specific organelles, such as mitochondria, lysosomes, ribosomes, or cilia, depending on its job. Which organelles would you expect to find in a muscle cell? Which organelles would a liver's cells need to clean the blood, break down fat, and detoxify alcohol?

Body Tissues and Membranes

Tissue samples and analysis provide important information to healthcare professionals. If a doctor suspects a disease such as cancer, she may do a biopsy, obtaining a tissue sample to examine under a microscope. Histologists [*hist* = tissue, *ologist* = specialist in the study of] work with pathologists, studying these tissues to determine the cause and treatment of a disease.

tissue
a group of cells of the same type working together for the same purpose

There are four main types of tissues, and all four are found throughout the body:

- *Connective tissue* includes cartilage, bones, body fat, and blood. This tissue is important for providing support, absorbing shock, and storing and transporting nutrients.
- *Nervous tissue* conducts impulses to and from body organs.
- *Muscular tissue* is important for movement.
- *Epithelial tissue* forms the skin that covers the outside of the body, as well as the membranes that cover the organs and line body cavities. This tissue forms a protective covering, allows the absorption of nutrients, helps to filter harmful substances out of the blood, and forms secretions.

Body Organs and Systems

organ
a distinct body structure made of different tissues working together for the same purpose

body system
a group of organs working together to perform a vital function in the body

Groups of tissues working together form **organs**. Each organ performs specific bodily functions. For example, the heart pumps blood and the vessels carry blood to all parts of the body. Groups of organs work together as **body systems**, such as the circulatory system. Different medical professions may specialize in the study of specific organs and systems. A cardiologist studies the heart and cardiovascular system. An oncologist studies cancers of the blood and other tissues. Internal medicine doctors study multiple body systems and their interaction. In health informatics, a medical coder looks up surgical procedures by body system and subcategorizes them by the specific organ.

Body systems work together as part of a complete organism (the human body) to control, move, support, protect, and reproduce. The human body systems are listed with their major organs and functions in Figure 5.9. The table also tells you which future chapters contain detailed information for each system. The acronym *SLIC MEN R RED* will help you to remember the names of the systems.

The tasks of the body systems often overlap, and some organs belong to more than one system. For example, the pancreas is part of both the digestive and endocrine systems. Some systems, such as the musculoskeletal system (muscles and bones), combine body parts that depend on each other so they can be studied together. All cells, organs, and body systems work together to keep your body healthy and maintain

Figure 5.9 Body Systems

Body System	Major Organs	Major Functions	Chapter
Skeletal	bones, ligaments	support, protection	9
Lymphatic (immune)	lymph nodes, tonsils, thymus, spleen	fluid return, immunity	13
Integumentary	skin, hair, nails	protection	9
Cardiovascular	heart, blood, vessels	transportation	13
Muscular	muscles, tendons	movement	9
Endocrine	glands, hormones	body communication and control	21
Nervous and special senses	brain, spinal cord, nerves, nose, mouth, ears, eyes, skin	body communication and control	21
Respiratory	pharynx, trachea, bronchi, lungs, alveoli, diaphragm	gas exchange	13
Reproductive	ovaries, uterus, fallopian tubes, testes, vas deferens, prostate	offspring production	17
Excretory (urinary)	kidneys, ureters, bladder, urethra	waste filtration	17
Digestive	stomach, liver, pancreas, intestines, colon	nutrient breakdown and absorption	17

a constant state of balance, or homeostasis (hoh-mee-oh-STAY-sihs) [*homeo* = same, *stasis* = stopping, controlling]. Diseases and disorders disturb this delicate balance.

Comparisons are a good learning tool because they help you organize and combine new information with ideas that are already familiar to you. The organizational structure of the human body, for example, can be compared to building a house (Figure 5.10 on the next page). When constructing a house, you need to begin with some basic building materials. The wood and nails you use to build the walls of a house are like the cells that make up body tissues. You need different types of body tissues to make body organs, just as the builder needs different kinds of wood, stone, and tile to make floors, counters, and walls. The fireplace, chimney, and vent of a house's heating system are like the lungs, bronchi, and trachea of your respiratory system. Just as the parts of the heating system work together for a common purpose, so do the organs of each body system.

The structural, plumbing, air conditioning, and electrical systems in a house can be compared to the skeletal, circulatory, respiratory, and nervous systems of the human body. Both a house and the human body need all of their systems to work together to provide a comfortable living environment. What other connections can you see between the organization of the body and the structures that form a house? Can you think of a different comparison?

Body Directions

standard anatomical position (SAP)
the agreed-upon reference for body position when studying anatomy; standing erect on two legs, facing frontward, with the arms at the sides and palms facing forward

Whether looking at a patient's body, writing about it in a medical chart, or coding patient information for the insurance company, all healthcare workers must use the same terms and points of reference. Medical examiners, surgeons, and medical illustrators all study the human body from the **standard anatomical position (SAP)**. When a cadaver (kuh-DAV-er)—a dead body—lies on the examination table for anatomical study, it is face up with the arms out to the side and palms facing up.

Directional terms are used to describe parts of the body or their position in reference to SAP. These terms usually occur in pairs with opposite meanings:

- **Anterior** [*ante* = front, before, *ior* = more toward] is the front side of the body; **posterior** [*poster/o* = back, behind, after] is the back. You can see the anterior view by looking in the mirror, but you need the reflection of another mirror to see the posterior.
- **Medial** [*med* = middle, *al* = pertaining to] refers to a point closer to the center of the body, while **lateral** [*later* = side] is toward the side. Men's clothing usually buttons and zips at the midline, but some women's clothing zips laterally at the hip.
- **Superior** [*super* = above, upon] means above or higher up on the body; **inferior** [*infer* = below] means lower down. The shoulders are superior to the hips but inferior to the ears.
- Sometimes we use more specific terms, such as **cranial** [*crani* = skull] to talk about a point closer to the head and **caudal** [*caud* = tail] for a point closer to the tailbone.

Figure 5.10 Comparing House Structure to Body Structure

House Diagram	House Structure Examples	Body Structure Examples	Body Diagram
	**Building Materials** nail wood stud brick shingle	**Cells** bone cell muscle cell skin cell	
	Groups of Materials wood rafters wood flooring brick siding roofing materials	**Tissues** connective tissue muscular tissue epithelial tissue	
	Basic Structures walls floors counters air conditioner fireplace chimney vent	**Organs** bones ligaments heart blood vessels lungs trachea skin	
	Structural System plumbing system air conditioning system electrical system	**Body System** skeletal system circulatory system respiratory system nervous system	
	Structure house	**Organism** human being	

- **Superficial** refers to the outside surface of the body, as opposed to **deep** tissues, which are farther below the surface. The heart is deep in the chest, and the ribs are more superficial.
- Left and right are labeled from the patient's perspective; the patient's right side is on your left.

Consider the differences and similarities of these directional terms for a two-legged creature compared to a four-legged creature (Figure 5.11). Which directional terms best describe the spine of a dog?

Descriptions of appendages (limbs) are based on their point of attachment to the body. For example, your arm is attached to your body at the shoulder, your hand is attached at the wrist, and your lower leg is attached at the knee. **Proximal** [*proxim* = near] indicates that the part being discussed is closer to the point of attachment, while **distal** [*dis* = apart] refers to a part that is farther away from the attachment site. As shown in Figure 5.12 on the next page, the proximal end of the humerus (a bone in your upper arm) is near the shoulder, and the distal end is at the elbow. The terms *proximal* and *distal* can also be used to describe internal organs. Like other terms based on SAP, these descriptions remain the same regardless of movement or repositioning of the body.

While the terms *anterior* and *ventral* as well as *posterior* and *dorsal* are frequently used interchangeably, there are specific differences in their meanings and uses. The terms *anterior* and *posterior* are used to describe the front and back of the body. The terms *ventral* [*ventr* = front] and *dorsal* [*dors* = back] describe body surfaces according to the way that joints flex.

Ventral (VEHN-truhl) surfaces move closer together when you bend a joint. They are generally lighter in color than dorsal surfaces and are often on the front side of the body. Try bending your arm at the elbow and you will see that the lighter-colored, ventral surfaces of your inner arm move toward each other. **Dorsal** (DOR-suhl) surfaces are located on the back of the body. They often receive the most sun, making them darker or hairier

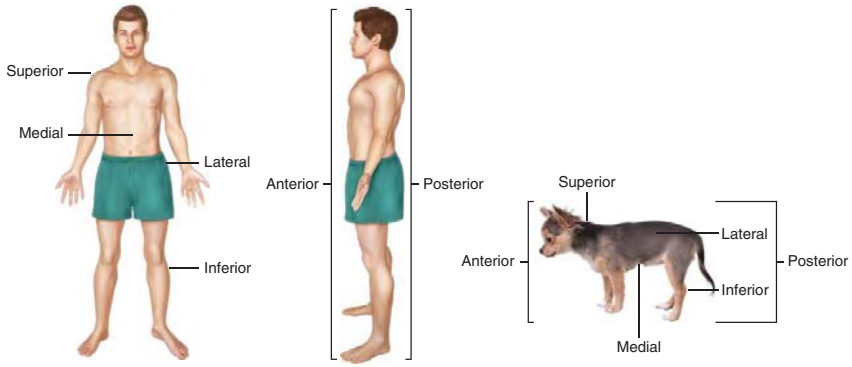

Figure 5.11 Directional terms usually come in pairs that have opposite meanings. What pairs of terms do you see in this figure? How are they opposite?

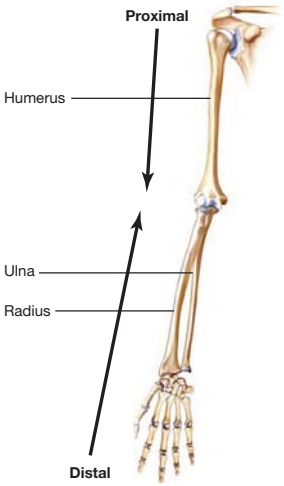

Figure 5.12 Proximal means close to the site of attachment. Distal means farther away from the site of attachment.

than ventral surfaces. The backside of the upper and lower arm is dorsal. These surfaces move away from each other as the elbow is bent.

The legs on the human forms in Figure 5.13 illustrate the differences between the terms *ventral* and *dorsal* as opposed to *anterior* and *posterior*. When the knee is bent, the two lighter, ventral surfaces pulled toward each other are on the backside of the legs. The back of the legs are posterior by position, but they are ventral based on the way they move. The surfaces of the legs turned to the front in SAP are anterior by position, but they are dorsal based on the way they move. The hip joints of a human rotate the dorsal side of the legs toward the front to support us in a standing position.

You can see the difference between humans and four-legged animals in Figure 5.13. If you rub the belly of a dog, you will notice that the light coloring of its ventral underbelly carries over onto the ventral inside of its legs. If a person lies on his or her back like a dog and lets his or her legs relax and roll out to the sides, the lighter (ventral) surface of the person's legs will also rotate more toward the front side of their body. When they stand on two legs, these ventral surfaces will rotate in toward the back of the body.

Body Regions and Sections

body region
an area of the body with a specific name, which is used as a point of reference when discussing anatomy

When a patient complains of pain, healthcare workers need an easy way to communicate with each other about the different areas of the patient's body where the pain may be. This is why the medical community has given names to different **body regions**. These names provide a common language so you can easily refer to different areas on the surface of the body.

Some of these terms, such as *abdomen* and *calf*, are part of our everyday language. Many of the terms come from the names of the bones under the skin that act as landmarks and give the areas their shape. For example, the head may be referred to as the cranial region, the thigh as the femoral region, and the shoulder blade area as the scapular region. The cervical region in the neck, thoracic region on the chest, and lumbar region of the lower back are named for their types of vertebrae. The gluteal region is named for the muscles of the buttocks.

Other regional terms are used more specifically in the medical field. For example, a nurse wraps the blood pressure cuff around the part of the upper arm called the brachial (BRAY-kee-uhl) region. Blood is usually drawn from the antecubital (an-tee-KYU-bih-tuhl) region on the inside of the elbow. The axillary (AK-suh-lair-ee) region is the term a medical assistant uses when taking a temperature under the arm. Understanding these regional terms helps you to communicate without additional explanation. The health informatics worker must know these regional terms to arrive at correct procedural codes.

The abdomen is such a large area that it is often divided into smaller sections, which are either quadrants or regions (Figure 5.14). This helps healthcare professionals focus on which abdominal organs may be involved when a patient complains of abdominal pain. One method of

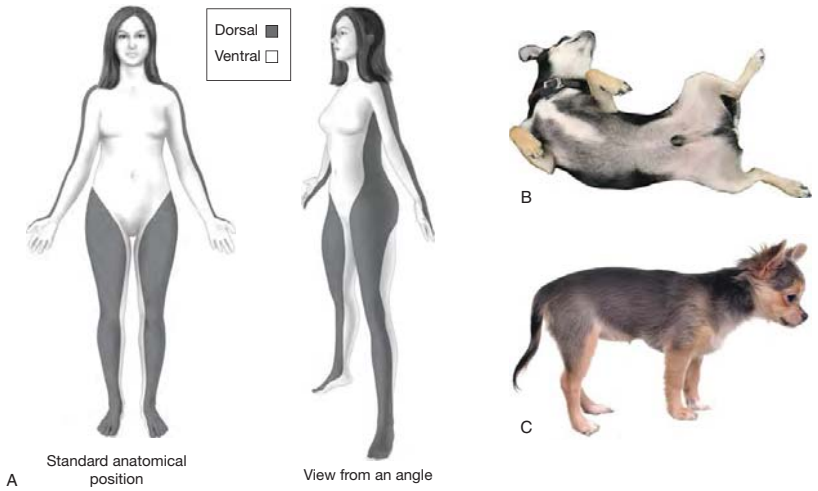

Figure 5.13 Figure A shows that, in SAP, the fronts of the legs are anterior by position but dorsal based on how they move. The backs of the legs are posterior by position but ventral based on movement. The person's open palms and angled legs in the second view show how ventral surfaces move toward an anterior position. Figures B and C show the ventral and dorsal surfaces on a four-legged animal as opposed to a two-legged human.

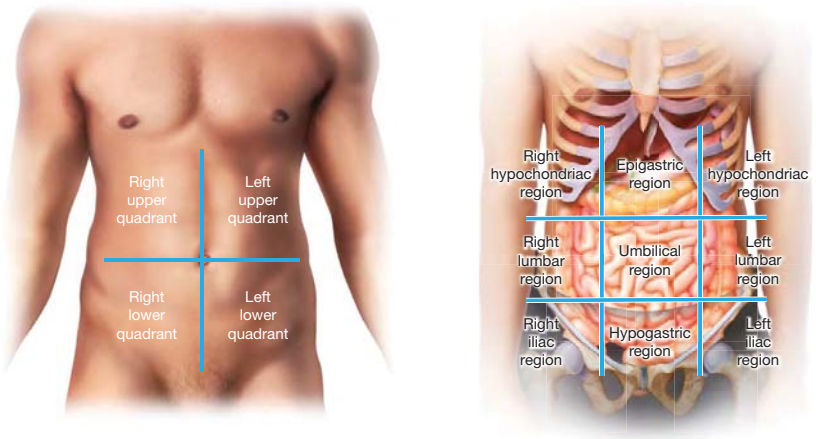

Figure 5.14 The abdomen can be divided into quadrants or regions. How might healthcare professionals use these quadrants and regions?

focusing in is to divide the abdomen it into four **abdominal quadrants** [*abdomin* = abdomen, *quad* = four] with the umbilicus, or *belly button*, at the center. Each of these quadrants contains just a few abdominal organs. The right upper quadrant (RUQ) contains the liver and gallbladder. The stomach, spleen, and pancreas lie in the left upper quadrant (LUQ). The appendix is a common cause of complaint in the right lower quadrant (RLQ), while the descending and sigmoid colon are in the lower left quadrant (LLQ). The small intestines are spread across the right and left lower quadrants.

abdominal region
one of nine equal areas of the abdomen that are named and used as reference points when discussing the body

A more detailed method is to divide the abdomen into nine **abdominal regions**, like a tic-tac-toe board, with the umbilicus at the center of the umbilical region. The epigastric region [*epi* = upon, *gastr* = stomach, *ic* = pertaining to] above it houses most of the stomach and pancreas. The right hypochondriac region [*hypo* = below, *chondr* = cartilage, *ac* = pertaining to] refers to the area under the cartilage of the ribcage, which contains the gallbladder and part of the liver, intestines, and right kidney. The left hypochondriac region holds the spleen and parts of the stomach, pancreas, colon, and left kidney. The right and left lumbar regions [*lumb* = lower back, loins] below the ribcage are named for the nearby lumbar vertebrae and contain parts of the intestines, kidneys, and colon. Below them, the right and left iliac regions are framed by the iliac bones of the hips. These regions contain the intestines and the appendix on the right and the sigmoid colon on the left. Keep in mind, the patient's right is your left! The hypogastric region [*hypo* = below, *gastr* = stomach, *ic* = pertaining to] is well below the stomach and includes the bladder, uterus (in females), and part of the small intestines.

These points of reference are helpful when a patient complains of abdominal pain. What organs would you expect to be coding treatments for if the progress notes indicated sharp pains in the patient's right iliac region?

Body Cavities

body cavity
a hollow space within the body that is lined by a membrane and contains bodily organs

The interior of the body is divided into **body cavities** that contain the vital organs (Figure 5.15). Each body cavity is separated by a membrane that covers and protects the organs within. They are also protected by bones. The **ventral cavity** in the front is surrounded by the ribs and pelvic bones. The **dorsal cavity** in the back is protected by the bones of the skull and vertebrae. There are also smaller sinus, orbital, oral, and nasal cavities in the head.

The diaphragm muscle separates the ventral cavity into the **thoracic** [*thorac* = chest] **cavity** above and the **abdominopelvic** [*abdomino* = abdomen, *pelv* = pelvis, hip region] **cavity** below. This separation helps to prevent infections from moving from one part of the body to another. The thoracic cavity includes the pericardial [*peri* = around, *cardi* = heart] cavity for the heart, surrounded by two pleural (PLOOR-uhl) [*pleur* = side, rib] cavities for the lungs. The abdominopelvic cavity includes the abdominal cavity for the digestive organs and the pelvic cavity that houses the reproductive organs, bladder, and rectum. The peritoneum (pair-ih-toh-NEE-um) is a membrane that separates the abdominal and pelvic cavities along an imaginary line from the top of the iliac bones of the hips down to the pelvic bone.

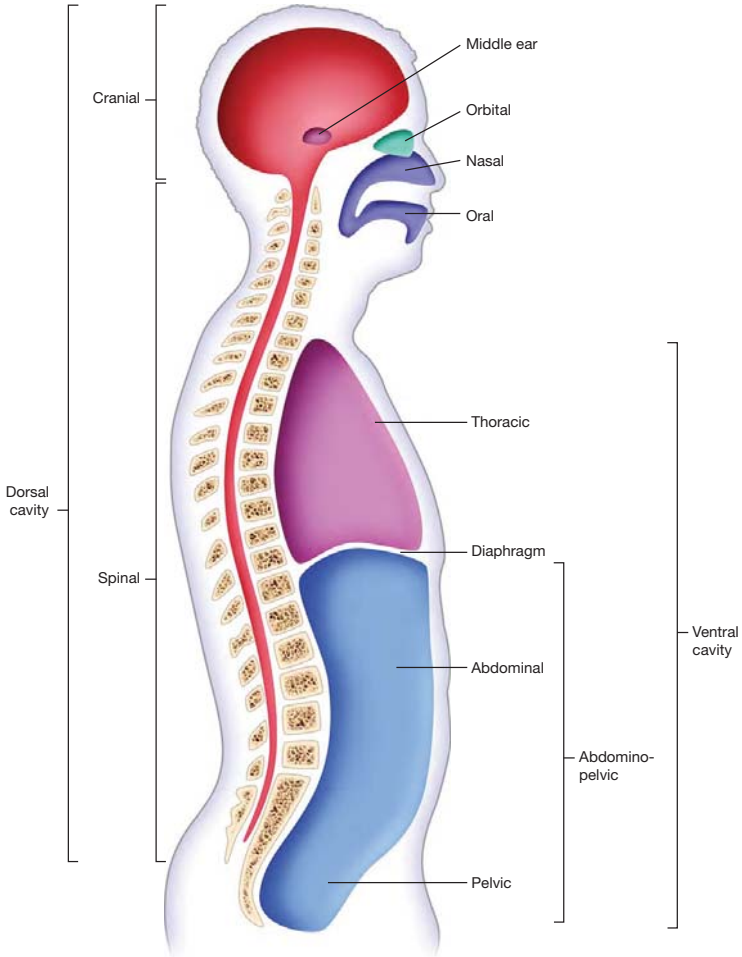

Figure 5.15 The interior of the body is divided into cavities that are separated by membranes. Which cavities are included in the head?

The dorsal cavity contains the **cranial cavity** for the brain and the **spinal cavity** for the spinal cord. In addition to the boney protection these cavities provide to the skull and vertebrae, they are lined by a membrane called the *meninges* (meh-NIHN-jeez).

Body Planes

body plane
a flat or level surface seen by cutting away part of the body through surgery or medical imaging to serve as a point of reference when discussing anatomy

Some medical professionals cut into the body with scalpels for surgery or dissection [*dis* = apart, *sect* = to cut, *ion* = action of]. Others use imaging technology to see inside the body without cutting it open. Body dissection and imaging technology both allow us to see the inside of the body in flat sections, or **body planes**. These planes help us refer more precisely to different points within the body.

If you look at an apple from the outside, you can only see the peel and overall shape. If you slice the apple from the top down through the core, you will see the inside, with the core down the middle and the seeds and flesh on each side of the core. If you had sliced the apple horizontally across the middle, you would have seen the core at the center, encircled by its seeds, and the apple flesh around that—a very different view.

Just as you can get a different view of the inside of an apple by cutting it in different directions, you can view the inside of a body along different planes, depending on what you are trying to see (Figure 5.16). The direction of the cut determines the name of the body plane:

- The **frontal plane**, also called the *coronal plane*, divides the body (or organ) into its front and back sections.
- The **sagittal** (SAJ-iht-uhl) **plane** divides the body, organ, or appendage into right and left sections. You can make a sagittal cut at various points along the width of the body. When the body is divided exactly down the midline, this is called the **midsagittal plane**. Zippers and buttons often appear on the midsagittal line. A midsagittal view of the head shows the different lobes of the brain.
- The **transverse** [*trans* = across] **plane** divides the body into top and bottom sections. It cuts across the body, perpendicular to the frontal and sagittal planes.
- Each section, or *plane*, shows different angles of different organs. Medical imaging technicians must be able to recognize the organs from different directions. These workers also know how superficial or deep in the body the organs are located.

Complete the *Map Your Reading* graphic organizer for the section you just read.

RECALL YOUR READING

1. Anatomy is organized in a hierarchy. Atoms bond to form molecules. Groups of molecules form _____, which are the basic structures of cells. Groups of similar cells join together to form _____. _____ are different types of tissues working together for the same purpose. They work together as _____ to maintain balance within the body.
2. Terms for body directions are based on standard _____ position, in which a person is standing erect, facing forward, with the arms at the sides and palms facing forward.
3. Abdominal _____ and _____ regions are two different ways of referring to areas of the belly.
4. Vital organs are protected inside _____ by membranes and bones.
5. Medical imaging views structures inside the body in flat _____.

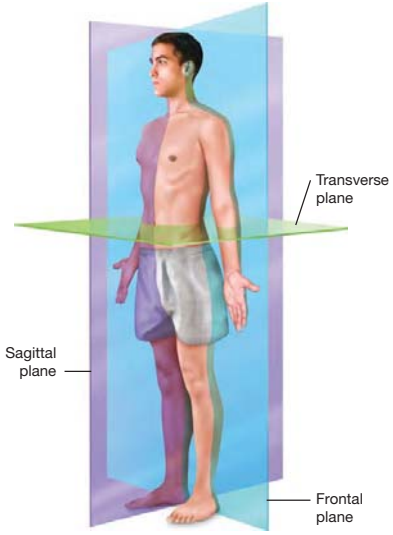

Three Planes

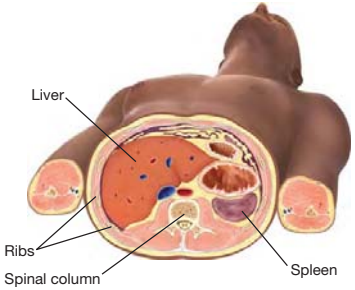

Transverse Plane

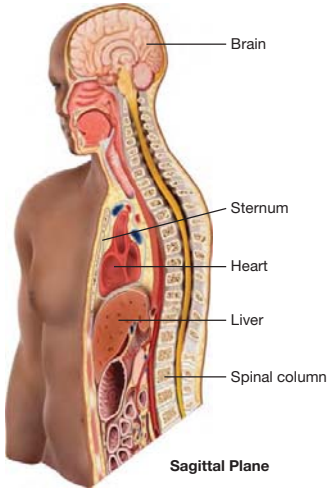

Sagittal Plane

Figure 5.16 The first image here illustrates the three planes you can use to divide the body. The next two images show cross-sections of two of those planes. Cutting along these planes allows you to view different organs and internal matter.

Chapter 5 Review

SUMMARY

- It is important to understand, speak, spell, and use medical terminology correctly in all medical careers.
- Medical terms are formed from Latin and Greek word parts.
- Abbreviations are a shortened way of writing medical terms. It is important that you only use the abbreviations approved by your facility.
- Plural forms of medical terms may not be formed in the same way as the plurals of common English words.
- Rules of pronunciation are helpful for sounding out medical terms, but you shouldn't spell medical terms based on how they sound.
- Mnemonic devices help you memorize new information.
- Anatomy refers to the parts of the body, while physiology refers to how the body works.
- Your body structures are built in an organized way, from atoms to a complete organism.
- Terms for body directions are based on standard anatomical position and are used to describe a body structure or its position.
- Body regions, such as abdominal quadrants and abdominal regions, provide a common set of terms for referring to areas of the body.
- Body cavities contain vital organs and are protected by membranes and bones.
- Body planes divide the body into sections to show structures inside the body.

MAXIMIZE YOUR PROFESSIONAL VOCABULARY

Build vocabulary with e-flash cards and games

Listed below are the essential, yellow-highlighted terms and the additional professional vocabulary terms that you encountered in this chapter. Complete the activities that follow the list to make all of these terms part of your everyday professional vocabulary.

abdominal quadrant
abdominal region
abdominopelvic cavity
acronyms
anatomy
anterior
body cavity
body plane
body region
body system
caudal
cell
cell membrane
combining vowel
cranial
cranial cavity
cytoplasm
deep
deoxyribonucleic acid (DNA)
distal
dorsal
dorsal cavity
endoplasmic reticulum (ER)
frontal plane
Golgi apparatus
inferior
lateral
lysosomes
medial
medical terminology
midsagittal plane
mitochondria
mnemonic device
nucleolus
nucleus
organ
organelle
physiology
plural
posterior
prefix
proximal
ribosomes
root word
sagittal plane
spinal cavity
standard anatomical position (SAP)
suffix
superficial
superior
thoracic cavity
tissue
transverse plane
vacuole
ventral
ventral cavity

Matching. Match each essential term from this chapter with the correct definition below by writing the letter of the definition next to the number of the essential term on a separate sheet of paper.

1. body plane
2. medical terminology
3. abdominal region
4. body system
5. anatomy
6. cell
7. tissue
8. standard anatomical position
9. organelle
10. body region
11. physiology
12. mnemonic device
13. organ
14. body cavity

a. a group of similar cells working together for the same purpose
b. special vocabulary that is used in healthcare and is often formed from Latin and Greek word parts
c. a hollow space within the body that is lined by a membrane and contains bodily organs
d. a distinct body structure made of different tissues working together for the same purpose
e. an area of the body with a specific name, which is used as a reference point when discussing anatomy
f. one of nine equal areas of the abdomen
g. a small group of organelles that fulfill a specific purpose and are held together by a membrane
h. the functions or inner workings of the body
i. a learning tool that helps students memorize information
j. the agreed-upon reference for body position when studying anatomy
k. a part of a cell that has a specific task
l. the physical structures or parts of the body
m. a flat or level surface seen by cutting away part of the body through surgery or medical imaging
n. a group of organs working together to perform a vital function in the body

15. Make flash cards for each of the medical word parts listed in this table, placing the word part on one side of the card and its definition and a visual aid on the other side. When you have your completed set of flash cards, follow the directions listed on the next page to play the Word Train Game.

Word Parts

Prefix	Root Word	Suffix	Prefix	Root Word	Suffix
ante-	abdomin/o	-ac		lumb/o	-us
dis-	cardi/o	-al		med/o	
endo-	caud/o	-cyte		pelv/o	
epi-	chondr/o	-ic		physi/o	
hypo-	crani/o	-ion		plasm/o	
infer-	cyt/o	-ior		pleur/o	
peri-	dors/o	-lysis		poster/o	
pre-	gastr/o	-ologist		proxim/o	
quad-	hist/o	-ology		reticul/o	
semi-	home/o	-plasm		sect/o	
super-	homin/o	-stasis		thorac/o	
trans-	infer/o	-ule		ventr/o	
	later/o	-um			

- The first player chooses a root word and a suffix and/or prefix card from his or her deck to form a medical term. The player lays the cards down with the word parts facing up, says the medical term that was created, and defines it.
- The next player must place a word part card on top of a word part that is already showing, then read the new term and define it.
- If a definition is challenged by other players, the cards are turned over and a definition is formed. If the definition was wrong, all of the cards on the table go to the hand of the person who defined the term incorrectly. If the definition is correct, all cards go to the challenger's hand.
- Play begins again with the next player placing a root word, suffix, and/or prefix card on the table and defining the new term. Players may not place an identical card on top of a card that is already displayed.
- The object of the game is to get rid of as many cards as possible. Players may only "pass" if they are unable to make a word with their current cards, or if they only have cards identical to those on the table. The game ends when no more words can be made. The player with the fewest cards left at the end of the game is the winner.

16. Choose a term from the list on page 168 to study. Create a poster for the term that includes its definition, a synonym, an antonym, another term with the same root, a sentence using the term, and a picture that helps you understand the term. If there is not a true antonym for the term, substitute a term that might be confused with the term you chose.

REFLECT ON YOUR READING

17. Review your sorted word list from the *Connect with Your Reading* activity at the beginning of the chapter. Make changes to your organization based on what you learned and remember from your reading of the chapter.

BUILD CORE SKILLS

18. **Critical Thinking.** Explain how nonstandard abbreviations could have a negative effect on the patient, the workers in your healthcare facility, and the workers in other healthcare facilities who receive your records.
19. **Critical Thinking.** Review the requirements a biologist uses to define a living thing. What evidence did you find in the chapter section on the cell to support the fact that a cell is alive?
20. **Writing.** Type the following paragraph into a word processor. Correct any errors found by the spell-check feature.

    All patience complained of stomach pane. The gastrenterologist noted stomach distention in every patient examined. The CNA reported that the patients complained of nawzea. Lab tests were ordered to confirm a diagnosis.

    a. What problems were corrected?
    b. What problems were missed?
    c. What problems were created?
21. **Reading.** Research the work of three of the following people who made important discoveries about the human cell. What were their roles in forming our current understanding of the cell? Be prepared to share your information with the class.
    a. Robert Hooke
    b. Anton Van Leeuwenhoek
    c. Randolf Virchow
    d. Theodor Schwann
    e. Camillo Golgi
    f. James Watson and Francis Crick

ACTIVATE YOUR LEARNING

22. Build the following "edible cell" model or create a model using different edible materials. Then answer the questions below.
    - cell membrane—slice of bread with the crust left on
    - cytoplasm—honey
    - nucleus and nucleolus—sucker or lollipop with the stick cut off
    - vacuoles—small pretzel twists
    - lysosomes—black jelly beans
    - mitochondria—gummy bears
    - endoplasmic reticulum—fruit leather cut and unrolled into long, thin strips
    - ribosomes—sprinkles
    - Golgi apparatus—gummy worms

    a. Explain how each of the edible cell parts looks like or represents the organelles of a cell.
    b. If you add a few more gummy bears, what type of cell would this be?
    c. If you add a few more black jellybeans, how does the cell's function change?
23. Trace a gingerbread man cookie cutter or draw the outline of a person with the arms and legs out to the sides. Draw a face and hair to show the front side and back side. Cut out the shape. Color the ventral surfaces on the front and back in green. Color the dorsal surfaces on the front and back in red. Add labels for ventral and dorsal on both the front and back sides.
24. Create an edible model of a person using a pickle or snack cake for the body, a marshmallow for the head, and toothpicks for arms and legs. Perform the following steps of an autopsy. Use the professional vocabulary you learned in this chapter to describe the body regions, directions, and planes as you write up the death report.
    a. For the gross assessment, examine the body surface. Note the location, size, shape, and color of any unusual markings. Draw an anterior and posterior view of the victim and mark the location of your findings.
    b. Weigh and measure the victim.
    c. Open the ventral body cavity with a deep, Y-shaped incision (see below). The arms of the Y should start at the anterior surface of the shoulders (A) and join at the inferior point of the sternum (B) to form a single cut that extends to the pubic area (C). Perform medial to lateral incisions from the umbilical area and down both sides (D) to open the abdominal cavity.

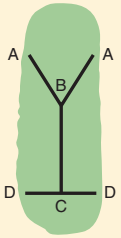

    d. Open the thoracic cavity to examine the "internal organs." Weigh and measure them. Describe your findings, noting any abnormalities.
    e. Decide on a cause of death and describe how your findings support that conclusion.

THINK AND ACT LIKE A HEALTHCARE WORKER

25. Suppose that you are an internal medicine doctor. Your patient is complaining of a stomachache. What locations would you examine based on your patient's complaint? Use professional vocabulary from this chapter in your description.
26. Suppose you hear or see a new term at work. List three different steps you can take to increase your understanding of this term.

GO TO THE SOURCE

27. Search the Internet for "stem cell research articles for high school students." Find an article that interests you and print it out. Then follow the steps listed here.
    a. Prepare for your reading by checking the source—who wrote the article? Why would this person be a qualified source on this topic? Who is the intended audience for this article?
    b. After reading the article title and subheadings, predict what you anticipate to learn from the article.
    c. Read the article. Then reread the article and underline any words that relate to or describe cells. Finally, read the article again and highlight main ideas about stem cell research.
    d. Review the underlined and highlighted material, looking for common themes or ideas. Use the template below to write a paragraph summarizing the article.

       In the article _____ (title), _____ (author) discusses _____ (main topic of the article). This information will be used in the future to _____.